



# ESDA

European Society of Dirofilariosis and Angiostrongylosis

## GUIDELINES FOR CLINICAL MANAGEMENT OF HUMAN *DIROFILARIA* INFECTIONS

Prepared for and approved by the Executive Board of ESDA

### Background

Zoonoses are infectious diseases of animals that can be transmitted to humans. Human dirofilariosis (caused by *Dirofilaria repens* and *Dirofilaria immitis*) are among the helminthic zoonoses most frequently diagnosed in Europe. Indeed, human infections with *Dirofilaria* parasites are diagnosed with increasing frequency in many European countries and are currently included in the so-called emerging diseases.

These guidelines, developed by the European Society for *Dirofilaria* and *Angiostrongylus*, are based on the latest information and include up-to-date recommendations for the diagnosis and clinical management of human dirofilariosis.

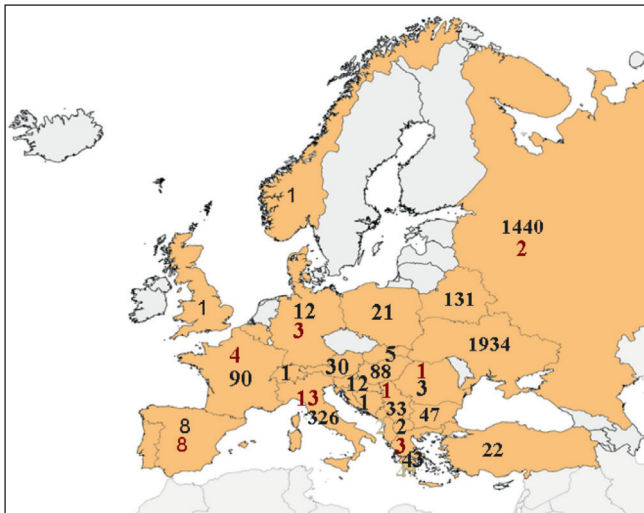
*For information on these infections in the dog, see the canine ESDA Guidelines.*

### Epidemiology

Human infections with *Dirofilaria* spp have been reported from all the European countries where canine infection is endemic. Humans are accidentally infected with *Dirofilaria* while living in or visiting those geographical areas where animal reservoirs, mostly dogs, and mosquito vectors are present in sufficient numbers

for an effective disease transmission. There is evidence that not only pets but wild carnivores may also serve as an infection source for humans. Even though mostly sporadic, human infections have risen sharply and have expanded broadly during the last two decades. Currently, most infections are caused by *Dirofilaria repens*, mainly in eastern European countries (more than 4,230 *vs* about 32 caused by *Dirofilaria immitis*). Most of these cases have been reported from Ukraine, Russian Federation, Italy, France, Austria, Hungary and Romania. *Dirofilaria immitis* infections are less frequent in Europe, but some cases have been reported even recently.

Humans can be accidental hosts of *Dirofilaria* spp. when they are bitten by an infected mosquito. In most cases, an abortive immune response occurs that prevents the complete development of the parasites. However, this exposure is enough to stimulate the production of specific antibodies by the immune system of the host. Indeed, the detection of anti-*Dirofilaria* antibodies in residents in endemic areas, without signs or symptoms related to human dirofilariosis, is an excellent tool to evaluate the level of risk of zoonotic transmission. Studies carried out by ELISA with somatic antigens or E/S antigens of *Dirofilaria* spp. in different endemic areas of Europe, Asia and America, indicate that where there is canine dirofilariosis there are always human infections by



**Figure 1** - Current distribution of reported cases of human dirofilariosis in Europe. In black appear the subcutaneous/ocular cases attributed to *D. repens* (approximately 4237); in red appear the pulmonary cases attributed to *D. immitis* (32). Cases of UK and Norway are probably imported.

these parasites and that the observed seroprevalences in humans are in agreement with the prevalences in the canine populations of the area.

## Clinical presentation

*Dirofilaria repens* infection in humans is characterized by different clinical presentations. The most frequent localizations are the eye region, eyelids and under the conjunctiva (in such a case the worm can be easily observed, sometimes actively moving), subcutaneous tissues (nodules) in the chest wall, upper and lower limb, neck and in other body regions including scrotum and penis. Even though less frequently, the parasite can be found in parenchymal organs such as lungs.

In most human cases of *Dirofilaria immitis* infection, the condition is characterized by the “classical” lung nodule (“coin lesion”) or nodules in other parenchymal organs, although recently several superficial localizations have been reported, mainly in the eye region.

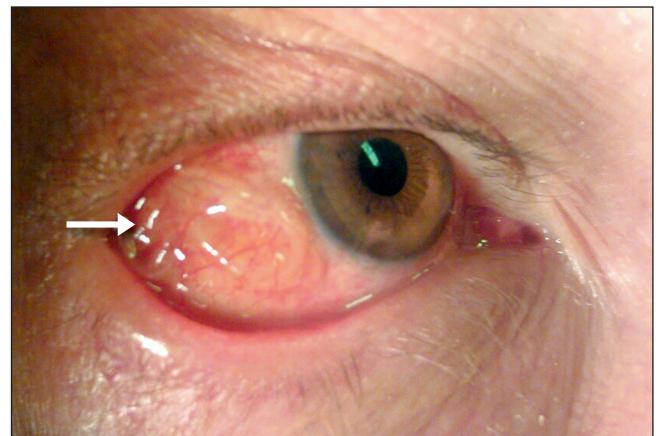
A wide scale study on the clinical presentation of human dirofilariosis has demonstrated several common demographic and clinical characteristics. Human dirofilariosis is most frequently described in patients around 40 years old, but the age of the patients can vary, mostly from 21-40 to 41-60 years. It was previously thought that there is no difference in prevalence between sexes. This however was based on a smaller series of patients. Currently, larger studies have demonstrated that women are much more often affected than men. The proportion of female to male patients, definitely established from the larger study, ranges from 67.4% to 74.4%, with a clear predominance of females.

The anatomical location of the parasite can vary, as can the clinical presentation. Infection may present as a subcutaneous nodule (at the time of presentation, during clinical examination but before surgery) or a cyst containing an encapsulated *Dirofilaria* (during and some-

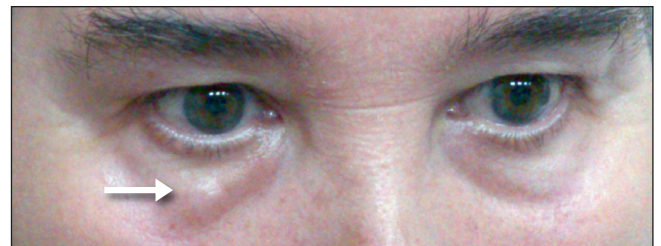
times just after the surgery). It is also possible to observe the parasite by naked eye, especially when located in the conjunctiva or in areas surrounding the eye area (eyelid, eyebrow, and adjacent anatomical structures). Ocular dirofilariosis represents approximately 40% of reported infections.

Rare cases of intravitreal and retroocular dirofilariosis have also been described. Other locations for nodules include the head and neck (18.9% - 25.3%), limbs (22.1% - 14.8%) and trunk (11.4% - 11.8%). Male genitalia (2.9% - 4.1%) and the female breast (2.7% - 2.5%) represent the frequent sites of *Dirofilaria* nodule/cyst location, but visceral location with non-encapsulated worms in the peritoneum, associated with signs of peritonitis has also been described (0.6%).

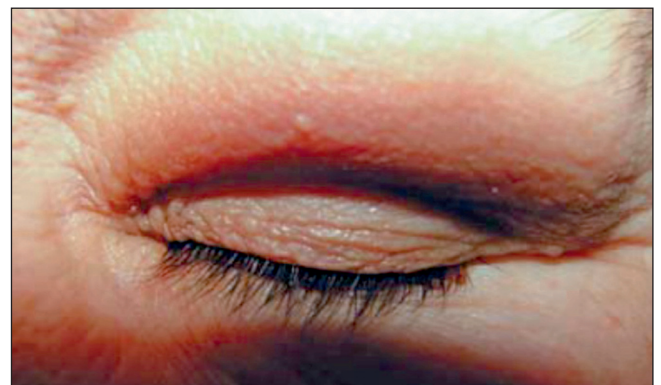
In the vast majority of patients the infection shows a single, painless subcutaneous nodule with no sign of in-



**Figure 2** - *Dirofilaria* in ocular conjunctiva visible (arrow) by naked eye.

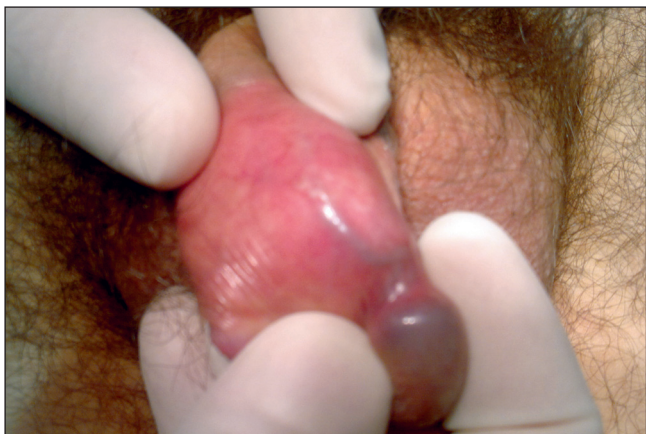

**Figure 3** - *Dirofilaria* nodule (arrow) at the right lower eyelid without inflammation.

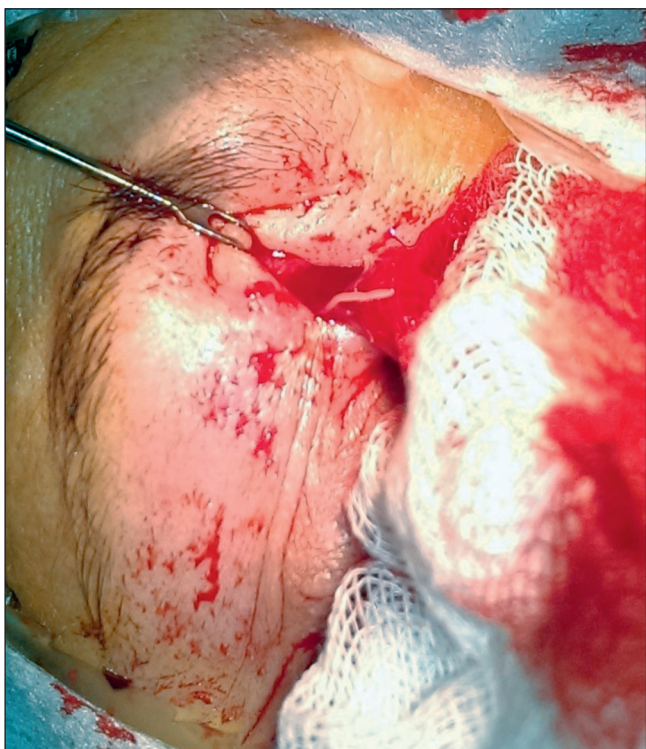

**Figure 4** - *Dirofilaria*-produced allergic oedema of the right eyebrow.





**Figure 5** - *Dirofilaria* location in penis manifested as red edematous spot.



**Figure 6** - Surgical removal of *Dirofilaria* from the right eyebrow (the same patient as in Fig. 4).

flammation. In the case of ocular location, nearly all the patients report a burning sensation, itching, and sometime painful eye movements. Patients report the feeling of a foreign body in the eye, and a history of the lower or upper eyelids or periorbital edema and swelling that are confirmed at clinical examination together with conjunctival hyperemia and tearing.

Another, often symptomatic location of *Dirofilaria*, is men genitalia and groin area with manifestation characterized by skin edema and hyperemia of the affected area.

## Diagnosis

Currently, due to the spreading into new geographical areas and to the increasing reports of disease associated

with infection, human dirofilariasis is becoming a challenge for physicians. As an “emerging” disease, it is not well known to the majority of physicians and it is not usually included in the list of differential diagnoses. There is no well-defined protocol for the diagnosis, and there is no reliable laboratory technique to confirm clinical suspicion. This all together results in delayed diagnosis and postponed surgical intervention, the only way to heal a patient.

Although a few human infections have been reported as presenting microfilaraemia, the search for circulating microfilariae is not a useful method for the diagnosis of *Dirofilaria* infections in humans.

## Serology

Irrespective of whether the inoculation of infective larvae of *Dirofilaria* spp. by a mosquito progresses or not to the appearance of preadult/adult worms, with or without formation of nodules, the infection stimulates the production of anti-*Dirofilaria* antibodies belonging to different isotypes (IgM, IgG or IgE).

As mentioned above, the detection of these antibodies is useful for determining the risk of infection and transmission in different geographical areas and are important for epidemiological studies.

In the clinical setting, serology is helpful for: 1. diagnosing clinical cases and 2. in connection to allergies.

### 1. Clinical cases

Serology can be used as a complementary technique to invasive or diagnostic imaging methods. Different antigenic complexes have been used to detect antibodies in clinical cases caused by both *D. repens* and *D. immitis*. However, complex antigens, although easy to obtain, may cause cross-reactions between different species of *Dirofilaria* and among other helminth species present in humans, especially *Toxocara canis*.

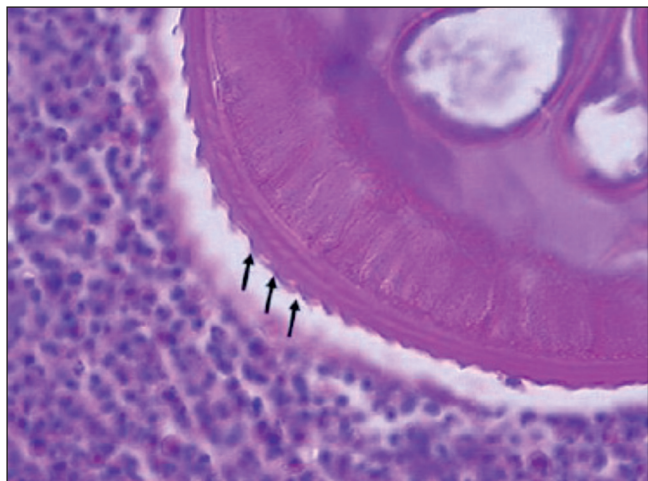
The specificity of ELISA with complex antigens can be improved by using isolated molecules present in antigenic complexes, such as the 35 and 22 kDa polypeptides in *D. immitis* and the 26-40 kDa polypeptides in *D. repens*.

Detection of antibodies against the dominant *Wolbachia* surface protein (WSP) is another way to improve the specificity of serology, since these bacteria are not present in helminth species other than filaridae.

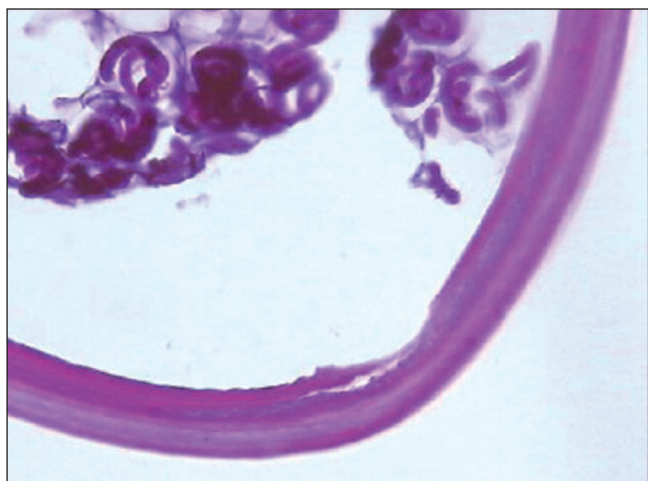
However, given the low pretest probability, the positive result of a serological analysis should be supplemented by other data such as radiography, medical history and place of residence, before deciding the application of invasive measures.

### 2. Relationship with allergies

It has been demonstrated that a significant percentage of atopic individuals with positive anti-*D. immitis* IgG serology, resident in an endemic area of dirofilariasis, also had high levels of anti-*D. immitis* IgE. This suggests an allergenic ability of *Dirofilaria* antigens. Therefore, it is advisable to include the analysis of specific IgE against two well-defined molecules of *D. immitis* (galectin and aldolase), in atopic residents in areas of dirofilariasis, when the origin of the allergy has yet to be determined.



**Figure 7** - Subcutaneous nodule from a patient affected by dirofilariosis, containing cross sections of an adult *Dirofilaria repens*. Note the longitudinal ridges on the cuticle (arrows) (from Genchi et al. Vector Borne Zoon Dis 2011, 11: 1307-1317).



**Figure 8** - Cross section of an adult *Dirofilaria immitis* taken from the pulmonary artery of an infected dog. Note the absence of cuticular ridges (from Genchi et al. Vector Borne Zoon Dis 2011, 11: 1307-1317).

### Histology

The examination of histological sections of worms and/or of the infected tissue collected during surgery allows the specific diagnosis. In case of *D. repens*, the typically indented cuticle allow the differentiation from *D. immitis*. In this species, the cuticular ridges are absent.

### Surgery

In the majority of patients, dirofilariosis is definitively diagnosed only following surgery. In most cases, before surgery, physicians usually suspect benign or malignant tumors, most often when the parasitic cyst/nodule is located in a woman breast. As a consequence, most patients have severe psychological problems before surgery, when the diagnosis is not clear and even after they are healed.

What are the main factors that contribute to making the preoperative diagnosis possible? First of all it is the patient's self-assessment of his/her health problem and the motivation to seek medical consultation. Then it is an anatomical location of encapsulated or free moving

*Dirofilaria*. For example, the eyes are usually regarded as a "sensitive" place, so in the case of an eye location the patient will seek a doctor consultation earlier. Presence of local inflammation of the surrounding tissues caused by the parasitic nodule strongly motivates a patient to seek a medical consultation. Particular phenomena local or distance migration of *Dirofilaria* can sometimes confuse the physician, but for those who have had previous experience, the migration phenomena leads to suspect dirofilariosis.

The most important factor that leads to timely and correct diagnosis before surgery is previous experience with and/or knowledge of the disease, as well as the motivation to make a detailed examination of the patient. It is well known from a number of published case reports and reviews that preliminary diagnosis is frequently wrong, especially in those countries where the disease is reported as rare or only considered an imported disease. For example, in the case of the Ukraine, where the highest number of human cases has been reported, in 1997 a centralized system of information, education of epidemiologists and medical doctors was created, together with reference laboratory confirmation of every human case, leading to a current percentage of pre-surgery clinical diagnosis as high as 75%.

Ultrasound examination, combined with color Doppler charting that allows the finding of some well-defined characteristics, is the only way for a pre-surgery specific diagnosis. By ultrasound examination (Fig. 9), nodules are oval and regular shaped with well-defined but jagged and fuzzy outer contours. The inner contents of the cyst appear hypoechoic.

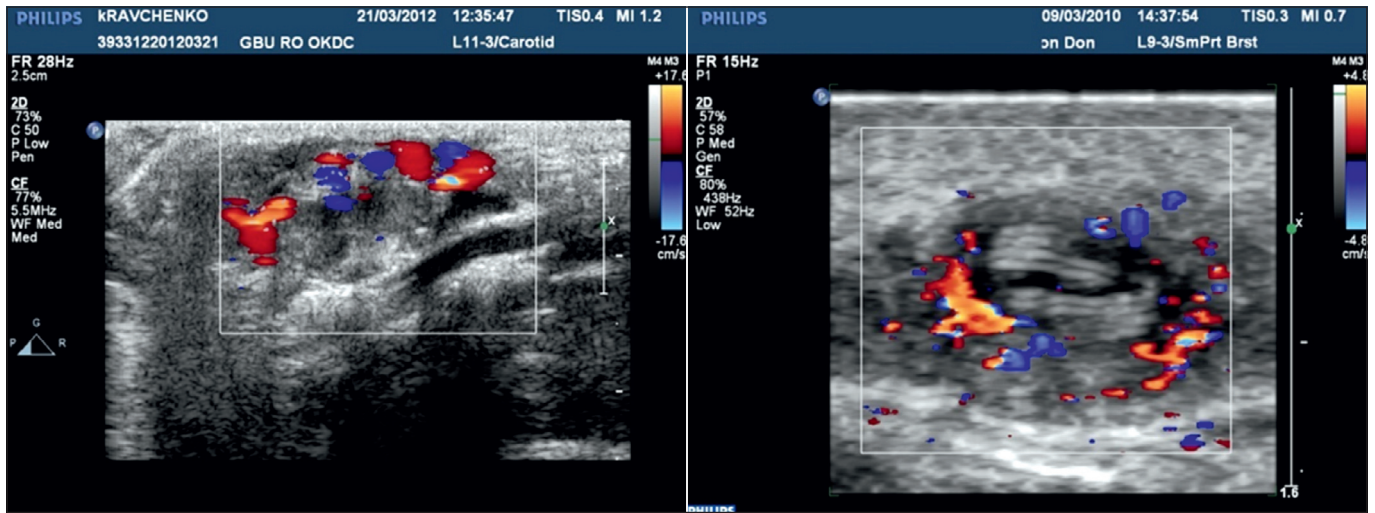
Inside the nodule there are clear internal echoes with linear winding hyperechoic textures, sometimes with visible spontaneous writhing movements, indicating the presence of live worms. Live worms look like multiple continuing and sharp but fine tubular textures. Dead worms show the same structures but they are motionless, non-continuous, mostly blurred and broken, with areas of high and low echo density.

Color Doppler examination clearly shows that none of the nodules has signs of internal or polar vascularity, the blood vessels are present at the periphery of the parasitic cyst wall. Power Doppler examination confirms the existence of blood flow only at the periphery of the nodules in the fibrotic capsule surrounding the worms and in adjacent tissues. These characteristics allow the attribution of the origin of the nodule to a helminthic origin, probably *Dirofilaria*, when epidemiological data is known.

### ESDA recommendations for physicians concerning the risk of human *Dirofilaria* infection

- In endemic areas, physicians should inform their clients that human dirofilariosis is an emerging infection.
- The abundance of mosquitoes in the environment and the prevalence of microfilaraemic dogs in the human habitat are the main risk of *Dirofilaria* infections for people.
- *The direct contact between infected dogs and humans is not a risk factor for humans to become infected, even in the domestic habitat. Dirofilaria* infections are





**A** **B**  
**Figure 9** - Ultrasound examination with color Doppler charting of a subcutaneous tumor (**A**) and a *Dirofilaria* nodule (**B**). The subcutaneous tumor has internal vascularization and is not surrounded by a capsule. The *Dirofilaria* nodule has well defined capsule (double arrow), it contains linear shapes, characteristic of *Dirofilaria* (arrow), and the blood vessels are present only in the capsule but not inside the nodule.

transmitted by the bite of infected mosquitoes. *The infection is not immediately transmitted*: a mosquito that has fed microfilaraemic blood is not able to transmit the infections until microfilariae have developed to infective stage. The development of larvae into the mosquitoes takes 10-14 days.

- Physicians should suggest to their clients that own dogs to ask their veterinarian practitioners to examine the dog for circulating microfilariae. In case of positivity, dogs should be treated with a microfilaricidal drug and prophylactic treatment to prevent patent infections should be initiated.

All rights reserved.

No part of this publication may be reproduced, stored in a retrieval system, or internet communication system or transmitted in any form, or by any means, electronic, mechanical, photocopying, recording or otherwise, without the prior permission, in writing, from the publisher.

© Copyright 2017 - EV/ESDA